

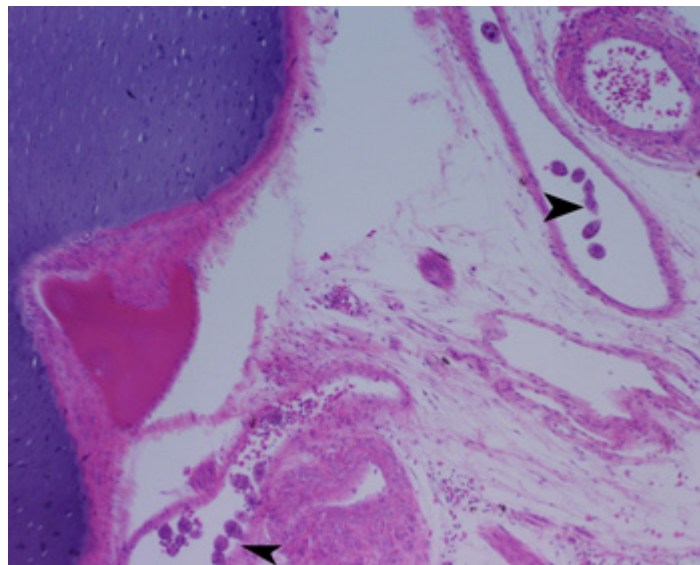


## **NAAH-TWG Slide of the Quarter (January to March 2007) - Effects of the pathogen *Uronema* on weedy sea dragons (F. Signathidae, *Phyllopteryx taeniolatus*) produced by aquaculture**

**Contributed by Gribbles Veterinary Pathology, Clayton (slide 06-1559B)**

### **Case History**

Over a period of several weeks, a large aquarium lost approximately 80 per cent of their adult weedy sea dragons, and 50 per cent of the juveniles. The dragons were fed live wild-caught mysid shrimp.



**Figure 1. - *Uronema* spp. in veins at the base of the skull of a leafy sea dragon (see arrowheads in the picture). x100**

### **Gross Findings**

An adult weedy sea dragon was received for post-mortem. There was a 2cm diameter area of skin discolouration, ulceration and pallor immediately caudal to the dorsal fin.

### **Microscopic Findings**

There was a marked expansion of the subcutaneous tissue around the circumference of the caudal abdominal cavity by low protein oedema and low numbers of mononuclear inflammatory cells.

There were large numbers of elongate oval ciliated protozoa, approximately 40 um in length, throughout the affected tissue. These organisms have a thin refractile wall, a single basophilic round eccentric nucleus and are filled with eosinophilic globules or refractile brown-to-black granular debris.



Focally, skeletal muscle fibres of the abdominal wall are separated by low protein oedema and organisms. Sections through abdominal organs show these organisms within the peritoneal cavity and within the kidney, which is moderately multicellular, with perivascular oedema. The organisms are also present around the spinal cord, in blood vessels, free in the peritoneal cavity, and within the gills, where there was a mild proliferative bronchitis.

### **Morphological Diagnosis**

Diffuse lymphocytic dermatitis and nephritis with focal oedema and *in situ* widespread protozoal organisms, subacute and severe.

### **Aetiological Diagnosis**

Consistent with *Uronema* spp. infection

### **Discussion**

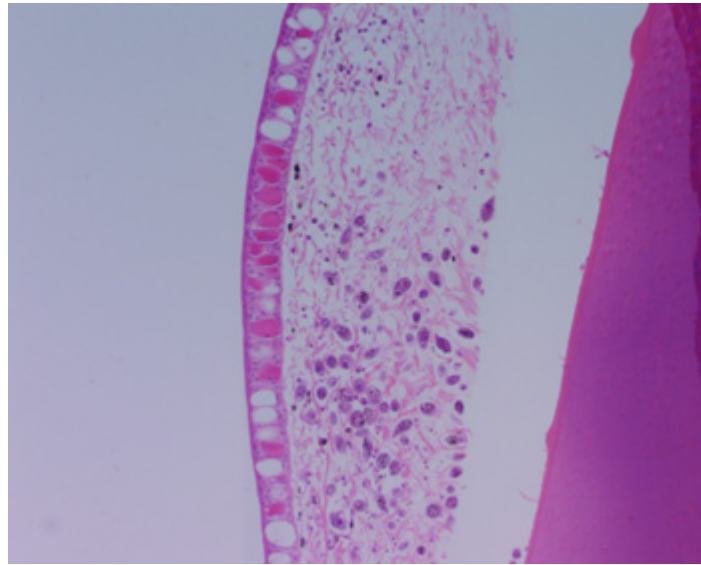
*Uronema* spp. is a free-living marine scuticociliated protozoan, which can be an opportunistic pathogen in aquaculture systems. Sea horses and sea dragons seem to be particularly susceptible. It is thought that environmental or other stress leading to immunosuppression allows the parasite to colonise the skin and gain entry to the body cavity and internal organs.

Skin scraping of the affected area during the post-mortem revealed numerous live *Uronema* spp. organisms. After the diagnosis was confirmed, the feeding of wild mysids ceased and was replaced by frozen mysids. The juvenile sea dragons accepted the change of food, but the adults did not.

Live mysids were reinstated to the adult sea dragons but with altered treatment aimed at reducing the number of *Uronema* organisms introduced to the tank. The seawater the mysids were received in was drained and replaced by fresh seawater before feeding to the weedy sea dragon, and feeding occurred immediately (previously the mysids had been stored for up to two days).

In addition, the cleaning of the weedy sea dragon tanks was upgraded so that more frequent vacuuming to remove organic matter was carried out. This organic matter provides a substrate upon which *Uronema* amplifies.

No deaths have occurred since these new management practices were instigated.



**Figure 2. - *Uronema* spp. in oedematous subcutaneous tissue. x100**

**NAAHTWG** - National Aquatic Animal Health Technical Working Group